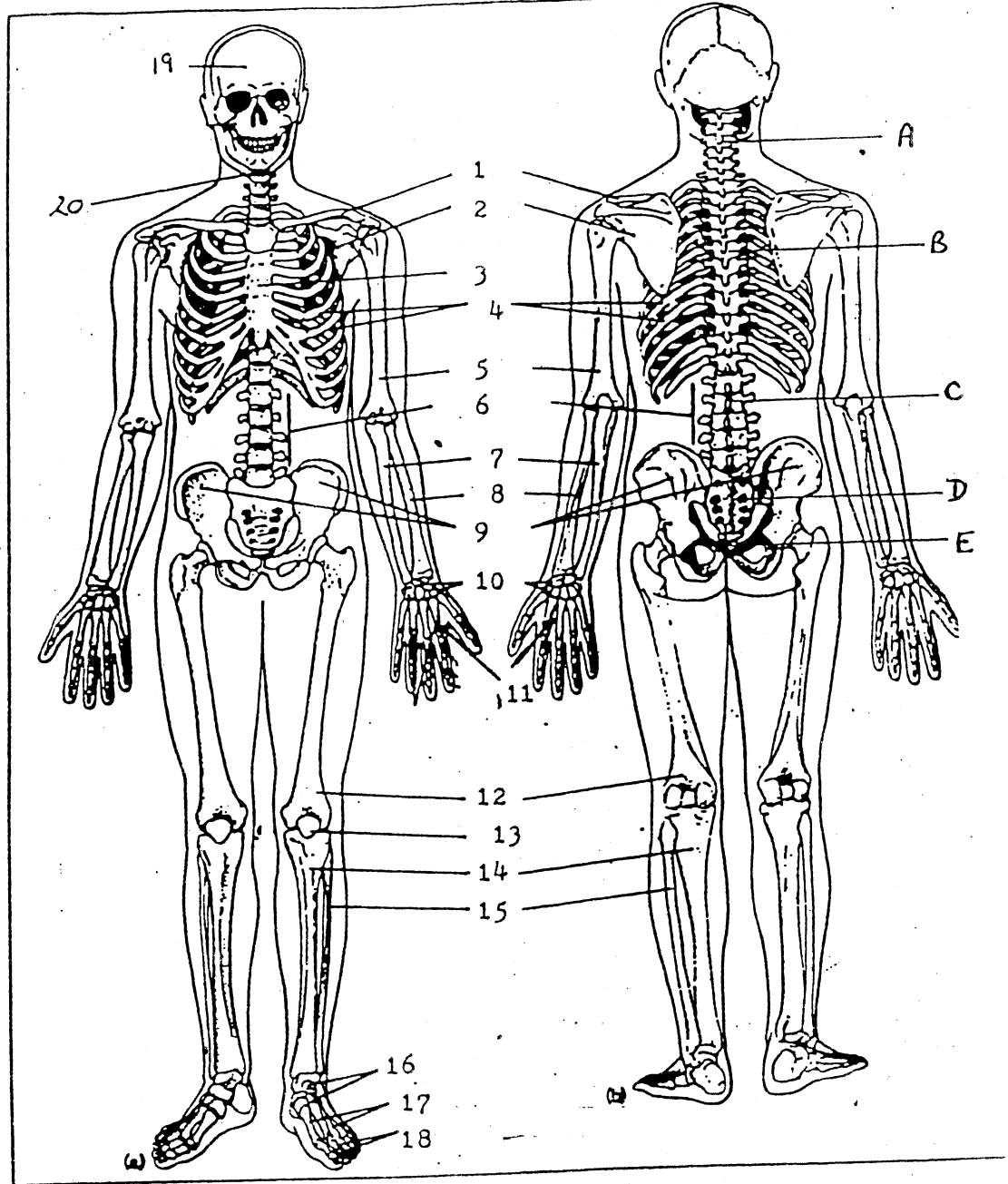


1. _____ Sternum *
2. _____ Mandible *
3. _____ Vertebrae *
4. _____ Femur
5. _____ Metatarsals
6. _____ Humerus
7. _____ Carpals
8. _____ Scapula
9. _____ Phalanges
10. _____ Ribs *
11. _____ Patella
12. _____ Pelvis
13. _____ Radius
14. _____ Ulna
15. _____ Fibula
16. _____ Cranium *
17. _____ Metacarpals
18. _____ Clavicle
19. _____ Tibia
20. _____ Tarsals



Regions of the Spinal Cord: *

- | | |
|--------------------|--------------------|
| 21. _____ Lumbar | 24. _____ Sacrum |
| 22. _____ Cervical | 25. _____ Thoracic |
| 23. _____ Coccyx | |

* BONES OF AXIAL SKELETON

ALL OTHER BONES ARE PART OF THE APPENDICULAR SKELETON